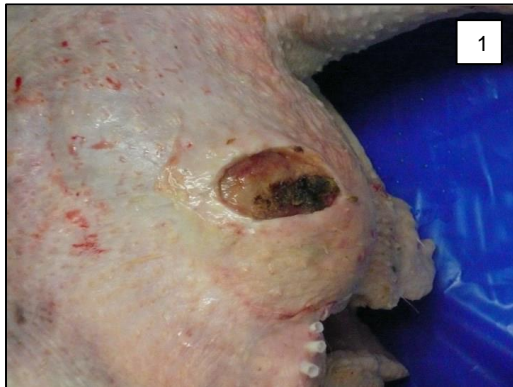

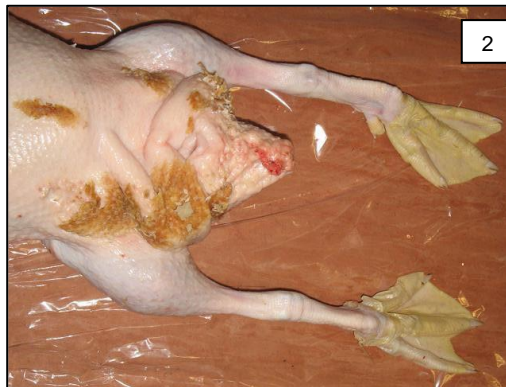# Conditions for Rejection of Poultry at Post Mortem

## Dermatitis in Poultry

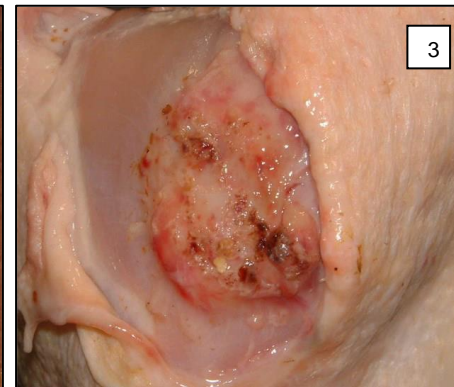
### Post Mortem Disposition



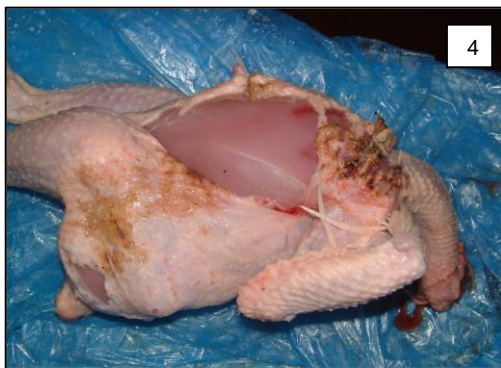**Figure 1:** Gangrenous dermatitis in a broiler.



**Figure 2:** Typical dermatitis in a duck.



**Figure 3:** Scabby hip syndrome: brown encrustation of the thigh skin.



**Figures 4 & 5:** Dermatitis probably caused by *Staphylococcus* infection

## FSS Responsibilities

### Post-mortem disposition

**Total rejection:** In generalised conditions the carcass must be rejected.

**Partial rejection:** If lesions are localised, the carcass may be passed as fit provided that the removal of the affected area has been carried out to the satisfaction of the OV and following an approved guideline developed by the FBO and agreed with the OV.

### Recording of the condition

The condition must be recorded under the "Dermatitis" entry under Post Mortem Inspection in OWS.

## Further Information

### Definition

Inflammation of the skin, often associated with bacterial infection.

### Remarks

There are different forms of dermatitis:

- Scabby hip dermatitis: characterised by brown encrustation of the thigh skin.
- Gangrenous dermatitis: distinguished by skin necrosis, subcutaneous fluid and underlying muscle with cooked appearance and haemorrhage. The skin of the legs, wings and abdomen is most frequently affected.

### Causes

This condition can be caused by

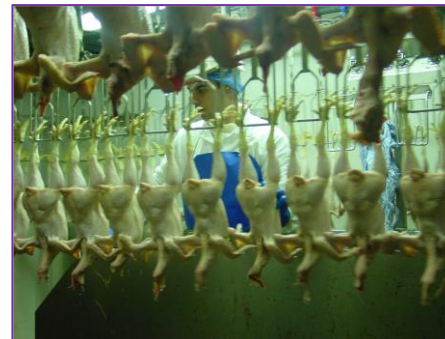- Contact with irritant substances that are present in the litter such as uric acid. The litter is often but not always wet when this condition arises.
- Scratching.

Secondary bacterial infection is a common consequence of the above causes.

Poor feathering, high stocking densities, poor litter condition, high lighting levels and poor handling have been identified as possible factors contributing to avian dermatitis.

### How is this information used?

Incidence of this condition is useful for the production company to identify management issues associated with stocking rates, drinker, ventilation and lighting management.



Poultry Meat  
Inspector  
assessing  
carcasses at  
whole bird  
inspection  
point.

### Acknowledgements to:

Pablo Hervas (OV) and Peter Cargill from Wyatt Poultry Vet Services, British Veterinary Poultry Association for help in developing the condition card.

**Pictures:** Pablo Hervas (OV), Carla Novau (OV) and Asier Pagazaurtundua (VM).